



Application Kit Silver Level

The application for Silver Level consists of:

- application form to be completed by the Owner/Applicant.
- application form to be completed by the Veterinarian. Please print a form for each assessing Veterinarian to complete. Only one form required if all X-rays were performed at one time.
- Verification form to be completed by owner.
- Veterinary Information sheets to help assist the Veterinarian in assessments.

Dogs are eligible to be certified from 12 months and older.

There will be no pass or fail grades.

All proof of testing should clearly identify the dog tested by microchip number, registered name and number.

X-rays to be performed by Board Certified Veterinarian following provided guidelines.

Completed Applications should be returned to the Queensland Bulldog Club Health Committee with EITHER application form completed by veterinarian

OR Proof of Testing form completed by owner with proof of testing, proof of result submission to ORCHID and the application fee to:

Queensland Bulldog Club Health Committee

C/- The Secretary

2 Poole Street

Leichardt Qld 4304

Or electronically lodged to:

qldbulldogclub@gmail.com



Queensland Bulldog Club

Silver Health Certificate Application

To Be Completed By Owner:

Registered Name

ANKC Registered Number Microchip Number

Date of Birth Sex Colour

Sire Name and Registration Number

Dam Name and Registration Number

Name of Applicant/Owner(s)

Address

Street Address

City

State

Postcode

Contact Number

Postal Address

Email

- Proof of submission of results and gradings to ORCHID attached
- I certify that all the information I have provided is true and correct.
- Please list Certification on QBC Website

Signature if Applicant/Owner

Date

To Be Completed By Assessing Veterinarian:

Date of Examination

Name of Examining Veterinary Clinic

Name of examining Veterinarian and Board Registration number

Veterinary Clinic Address

Phone Number

Please enter a valid phone number.

Email

I have verified the permanent identification of the dog by scanning the microchip and the information matches the permanent identification provided on this form and the original certificate of pedigree issued by an ANKC Ltd (Dogs Australia) Member Body.

- Yes the Microchip matches
- No the Microchip does not Match

I have read the Information Sheets for Veterinarians. I can confirm that I have sighted X-rays or X-rayed the dog for the following (please select applicable testing) in accordance with the guidelines and have submitted where appropriate for scoring and recording in ORCHID database:

- Hips Submission no.
- Spine Submission no.
- Elbows Submission no.
- Thoracic Inlet and Tracheal Diameter Ratio ≥ 0.12

Signature of Veterinarian

Clinic Stamp

Proof of Testing Form To Be Completed By Owner

Registered Name

ANKC Registered Number Microchip Number

Proof of testing attached:

- Hips Submission no.
- Spine Submission no.
- Elbows Submission no.
- Thoracic Inlet and Tracheal Diameter Ratio ≥ 0.12

I certify that all the information I have provided is true and correct.

Signature if Applicant/Owner

Date

Information Sheets For Vets

Hip X-Rays

Diagnostic Imaging Panellists:

Dr Roger Lavelle VIC lavellesdiagnosticimaging@gmail.com

Dr Mariano Makara NSW www.vetscoring.com

Dr Jenny Richardson WA Jen.Richardson@iinet.net.au

Dr Ana Hayes VIC anahayes18@icloud.com

Testing Procedures:

Digital x-rays must be in DICOM format Radiographs are obtained under sedation or anesthesia for several reasons:

To minimize stress to the patient.

To permit precise positioning of the pelvis and hips.

To remove the need for the animal to be held, as x-rays are potentially hazardous for anyone doing so.

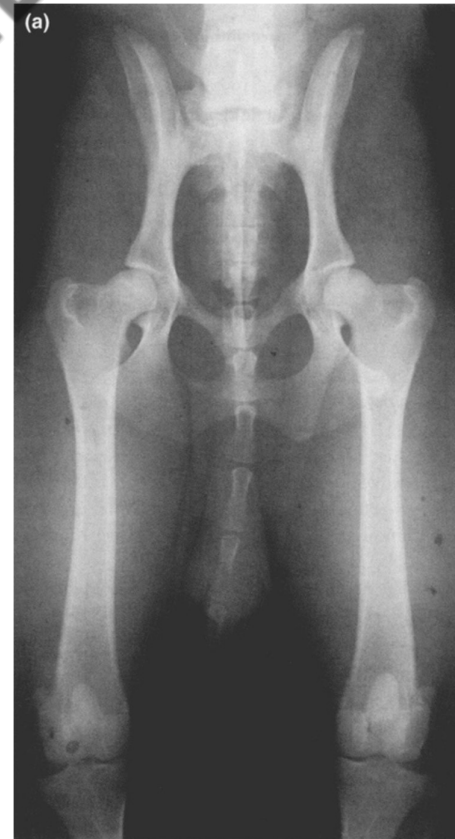Positioning: The radiographic view required is the extended ventrodorsal (VD) view. The dog is positioned on its back with its hindlegs extended caudally, resulting in a position similar to that of a standing human. The femora must be positioned parallel to each other and for this, the stifles are rotated slightly medially and held in position with a tie or tape so that they lie in the sagittal plane with the patella superimposed over the centre of the distal femur. This position allows the femoral neck to be seen clearly, without superimposition by the greater trochanter and facilitates the detection of new bone on the femoral neck.

Centring of the x-ray beam must be at the level of the hip joints, which can be achieved by palpation of bony landmarks such as the pubic symphysis and greater trochanters. Centring further cranially or further caudally will distort the appearance of the hip joints. Collimation must be sufficient to include the pelvis, but it is not necessary to include the stifles; to do so requires either incorrect centring or an unacceptably large area to be irradiated.

It is important to avoid tilting the dog to the side (lateral rotation) as this will alter the appearance of the hips and may worsen the score, since the hip that is closer to the table may appear artefactually subluxated. It is also important that the technical quality of the image is of a high standard with optimum contrast and definition and all the necessary labelling.

Reference

DENNIS R. Interpretation and use of BVA/KC hip scores in dogs. In Practice. BMJ Publishing Group Limited; 2012 Apr 16;34:178–194. Dr Mariano Makara. <https://vetscoring.com/radiographic-technique/>



Spine X-Rays

Diagnostic Imaging Panellists:

Dr Roger Lavelle VIC lavellesdiagnosticimaging@gmail.com

Dr Mariano Makara NSW www.vetscoring.com

Dr Jenny Richardson WA Jen.Richardson@iinet.net.au

Dr Ana Hayes VIC anahayes18@icloud.com

Testing Procedures:

Digital x-rays must be in DICOM format Radiographs are obtained under sedation or anaesthesia.

Positioning:

Thoracic, thoracolumbar and lumbar spine, lateral view

- Place the dog in either lateral recumbency using sponges to make the spine parallel to the tabletop.
- Use a sponge beneath the sternum to achieve lateral positioning.
- Attempt to achieve this lateral positioning of the entire body
- Sandbags can be placed on the neck to help position the dog.
- The forelimbs are extended and can be held with sandbags or tied to the table.
- The pelvic limbs are in neutral position or extended being placed one over the other and tied to the tabletop or held with sandbags.
- The vertically directed beam is perpendicular to the tabletop and centered on T6-7 for the thoracic spine, on T13-L1 for the thoracolumbar spine and on L3-4. (3 lateral views)

Thoracic, thoracolumbar and lumbar spine, ventrodorsal view

- Place the sedated dog in dorsal recumbency.
- Sandbags may be positioned lateral to the thorax and abdomen.
- The body may be positioned so the abdomen or thorax is in a trough or held by a compression band.
- The forelimbs are pulled cranially and held by sandbags or ropes.
- The pelvic limbs can be in neutral position either held or tied to the table
- The vertically directed beam is centered on T6-7 for the thoracic spine, on T13-L1 for the thoracolumbar spine and on L3-4. (3 ventrodorsal views)

Reference - Dr Mariano Makara. <https://vetscoring.com/radiographic-technique/>

Thoracic Inlet and Tracheal Diameter X-rays

Details about the Condition: Tracheal hypoplasia is a narrowing of the trachea that is present from birth. The trachea is made up of multiple cartilage rings, and in affected dogs the growth of these ring is inadequate. The trachea does not always grow at the same rate as a puppy and in some cases, it will require careful management until the puppy outgrows the condition.

Tracheal hypoplasia is one component of brachycephalic airway obstruction complex.

Affected animals may present with stridor (wheeze), dyspnoea (laboured breathing), reduced exercise tolerance and coughing. Excitement can make the condition worse.

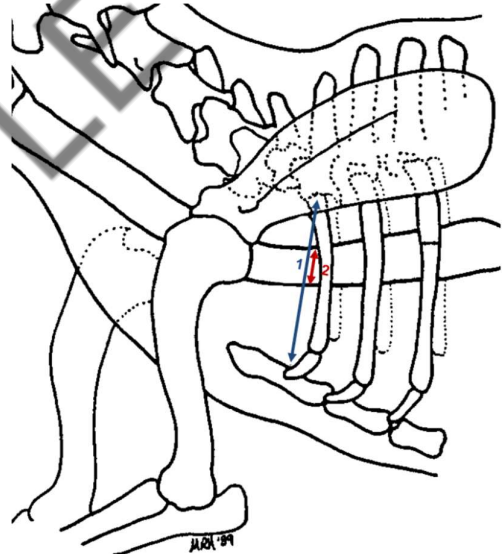
Testing Procedure: Tracheal hypoplasia is diagnosed by Xray over the age of 12 months. Dog may be awake or sedated. If sedated endotracheal tube must not influence tracheal diameter.

Evaluation of the radiographs should include the following:

1. Assessment of the pulmonary parenchyma for pneumonia, pulmonary oedema, or other pathology.
2. Assessment of the mainstem bronchi and trachea for collapse
3. Measurement of the thoracic inlet and tracheal diameter.

Thoracic Inlet Measured from the ventral aspect of the vertebral column at the midpoint of the most cranial rib to the dorsal surface of the manubrium (1st sternum) at its point of minimal thickness

The tracheal diameter Measured between the internal surfaces of the tracheal wall oriented perpendicularly to the tracheal long axis. This measurement performed where the long axis of the trachea crosses the midpoint of the tracheal lumen



Interpreting Results: Measurements taken at the Thoracic Inlet, TI (number 1 in the diagram) and the diameter of the Trachea TD (Number 2) are then written as a ratio. Ratio is calculated by $TD \div TI$.

Dr Mariano Makara. <https://vetscoring.com/radiographic-technique>

Elbow X-Rays

Diagnostic Imaging Panellists:

Dr Roger Lavelle VIC lavellesdiagnosticimaging@gmail.com

Dr Mariano Makara NSW www.vetscoring.com

Dr Jenny Richardson WA Jen.Richardson@iinet.net.au

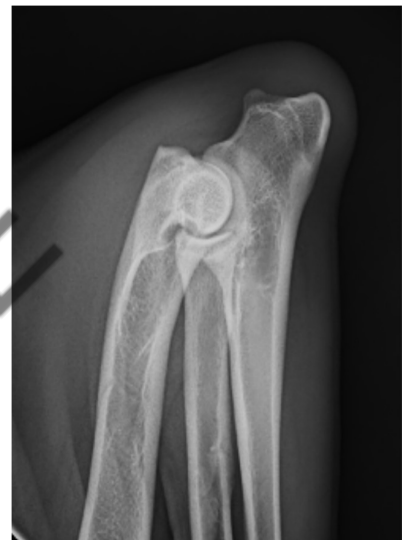Dr Ana Hayes VIC anahayes18@icloud.com

Testing Procedures:

Digital x-rays must be in DICOM format Radiographs are obtained under sedation or anesthesia.

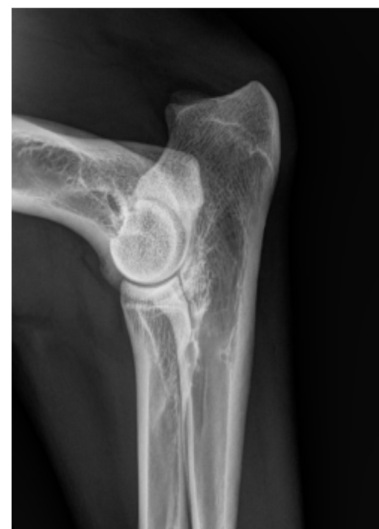Hyperflexed medial to lateral view (mandatory)

- Place the patient in lateral recumbency with the affected limb next to the tabletop.
- Forcefully pull the limb downward and cranially.
- Position the limb so that the elbow joint is a hyperflexed position. Make sure the carpus stays in a true lateral position, move the carpus toward the neck to hyperflex the elbow joint. This will help keep the elbow joint in a true lateral position.
- Use sandbags to hold the limb in position.
- Arch the head and neck dorsally using sandbags to hold the position.
- Pull the unaffected leg caudally and hold it with sandbags or tie to the tabletop.
- Sandbags can be used to hold the pelvic limbs.
- X-ray beam direction: The vertically directed x-ray beam is centered on the elbow joint.



Lateral view (highly recommended)

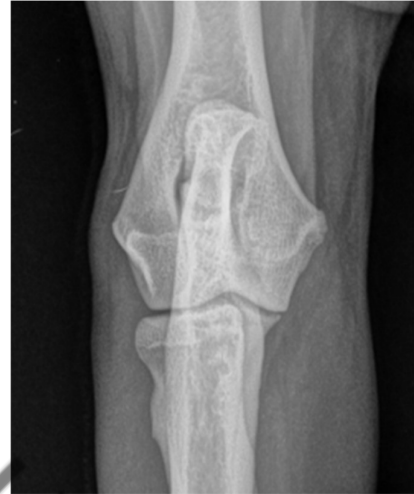- Position the patient in a lateral recumbent position with the elbow to be imaged down.
- Position the target limb cranially and ventrally and pull the opposite leg caudally
- Flex the elbow to a 90 degree angle
- Place the patient in lateral recumbency with the affected limb next to the tabletop.
- Forcefully pull the limb downward and cranially
- Flex the elbow to a 90 degree angle.
- Use sandbags to hold the limb in position.
- Arch the head and neck dorsally using sandbags to hold the position.
- Pull the unaffected leg caudally and hold it with sandbags or tie to the tabletop.



- Sandbags can be used to hold the pelvic limbs.
- X-ray beam direction: The vertically directed x-ray beam is centered on the elbow joint.

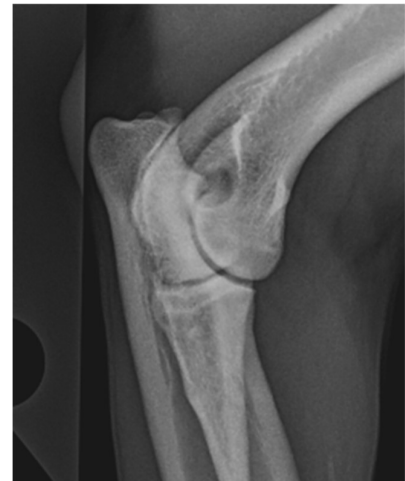Craniocaudal view (encouraged)

- The patient is placed in sternal recumbency with the forelimb to be studied pulled as far cranially as possible and held by sandbags or tied to the table.
- The opposite forelimb can be left in a neutral position.
- Hyperextend the dog's neck and pull the head laterally toward the unaffected limb so that it is not within the primary beam.
- This positioning places the radius and ulna parallel to the tabletop but the humerus remains at an angle to the tabletop.
- X-ray beam direction: The vertically directed beam is angled distoproximally around 10 to 20 degrees in an effort to display the joint surfaces better.



Cranial 25-degree lateral-caudomedial oblique projection(encouraged)

- The patient is placed in sternal recumbency with the forelimb to be studied pulled as far cranially as possible and held by sandbags or tied to the table.
- Rotate the patient approximately 25° medially. The dog's head can be positioned laterally toward the unaffected limb so that it is not within the primary beam for both oblique views.
- The opposite forelimb can be left in a neutral position.
- X-ray beam direction: The vertically directed beam is perpendicular to the tabletop for the oblique views.



Reference - Dr Mariano Makara. <https://vetscoring.com/radiographic-technique/>

Amendments

11/5/2023	Changed AVA number to board number Adjusted footer to show level and page numbers. Removal of ETT/RFGS requirement to Health star until testing is available statewide. Box for ACER submission number.
3/11/2023	Changes to allow for submission for certification by owner by providing copies of reports.
9/4/2026	Gold level amended to Silver level

SAMPLE